

# Thoracic Involvement of Liver Hydatid Cyst – Case Series and Review of Literature

Sorin Berbece<sup>1</sup>, Cristian Blajut<sup>2</sup>, Silviu Ciurea<sup>2</sup>, Codrut Stanescu<sup>2</sup>, Irinel Popescu<sup>2</sup>

**Corresponding author:**

Sorin Berbece, MD  
Dunarea de Jos University,  
Faculty of Medicine and Pharmacy  
Galati, Romania  
E-mail: sorin.berbece@gmail.com

<sup>1</sup>Dunarea de Jos University, Faculty of Medicine and Pharmacy, Galati, Romania

<sup>2</sup>Center of General Surgery and Liver Transplantation, Fundeni Clinical Institute, Bucharest, Romania

## ABSTRACT

**Aims:** Hydatidosis, caused by *Echinococcus granulosus*, is an endemic parasitic disease in Mediterranean countries. The most frequent anatomic locations are liver and lung. Intrathoracic rupture of hydatid cysts situated in the hepatic dome is a serious complication resulting in damage to the pleura, pulmonary parenchyma, and bronchi.

**Material and Methods:** From 2005 to 2014 we operated on 853 patients with liver hydatid cysts, 4 of them having intrathoracic rupture of a hepatic hydatid cyst. Hepatic and thoracic ultrasonography was performed in all cases. The diagnosis of intrathoracic rupture of a liver cyst was confirmed in all patients.

**Results:** In two cases a combined thoracic and abdominal approach was used, in one case a thoracic approach with phrenotomy was preferred, and in one case an abdominal approach with phrenotomy was chosen. The postoperative course was somewhat uneventful in 3 cases, but 1 patient died due to pulmonary embolism.

**Conclusions:** The therapeutic approach depends on ultrasonographic and computer tomography findings (CT). We believe CT-scan to be the best examination for assessing biliary, hepatic, diaphragmatic, and pleuropulmonary lesions. An abdominal approach is necessary when biliary duct drainage is required, and it may be sufficient in cases of direct rupture into the bronchi.

**Key words:** hydatid disease, echinococcosis complications, intrathoracic rupture of hydatid cysts, therapeutic approach

## INTRODUCTION

Hydatid disease, caused by *Echinococcus granulosus*, is endemic in some countries, particularly those in which sheep and cattle are raised, such as the Mediterranean countries, the Middle East, South America, Australia, and New Zealand. In Romania it is particularly common in the rural population; the surgical incidence of hydatidosis in Romania is 5,6/100,000 inhabitants.

Intrathoracic rupture of hydatid cysts situated in the upper liver surface is a dreadful complication. Damage to the pleura, pulmonary parenchyma,

Received: 14.01.2016

Accepted: 23.02.2016

and bronchi is serious. Despite the advances in modern imaging, problems associated with the treatment of this complication is still challenging and often difficult to resolve. In this case series report we present our experience with the surgical management of 4 successive cases of intrathoracic rupture of a hepatic hydatid cyst.

**MATERIALS AND METHODS**

During the 10 years from January 2005 to December 2014 we operated on 4 patients with intrathoracic rupture of hepatic hydatid cysts. There were 3 women and 1 men, aged 24 years, 32 years, 41 years and 55 years respectively.

All patients had symptoms at the time of operation. The most frequent symptoms were lower chest pain and a productive cough (*table 1*).

Hepatic and thoracic ultrasonography and CT-scan was performed in all cases. In all cases ultrasonography confirmed the presence of a multivesicular (3 cases) or pseudotumoral (1 case) hepatic hydatid cyst.

Computed tomography (CT) scanning was performed in all cases and showed thoracic and liver contiguous lesions (*fig. 1*); the diaphragmatic hole was not clearly confirmed in 2 cases. Magnetic resonance imaging (MRI) was not performed.

In two cases a combined thoracic and abdominal approach was used. For the thoracic approach a right posterolateral thoracotomy was chosen, and for abdominal approach a median laparotomy was preferred. In one case (case 1) we performed pulmonary resection with partial cystectomy and drainage of the residual cavity of liver hydatid cyst and placement of a

**Table 1 - Clinical findings of patients**

Symptom	Number of patients
- Chest pain	4
- Cough and sputum	4
- Hemoptysis	3
- Vomiting	2
- Dyspnea	3
- Pleural effusion	2
- Bile-stained sputum	1

Kehr t-tube drainage in the common bile duct (CBD). In the other case (case 2) we performed liver resection for the liver hydatid cyst, intraoperative ERCP and thoracic collection drainage.

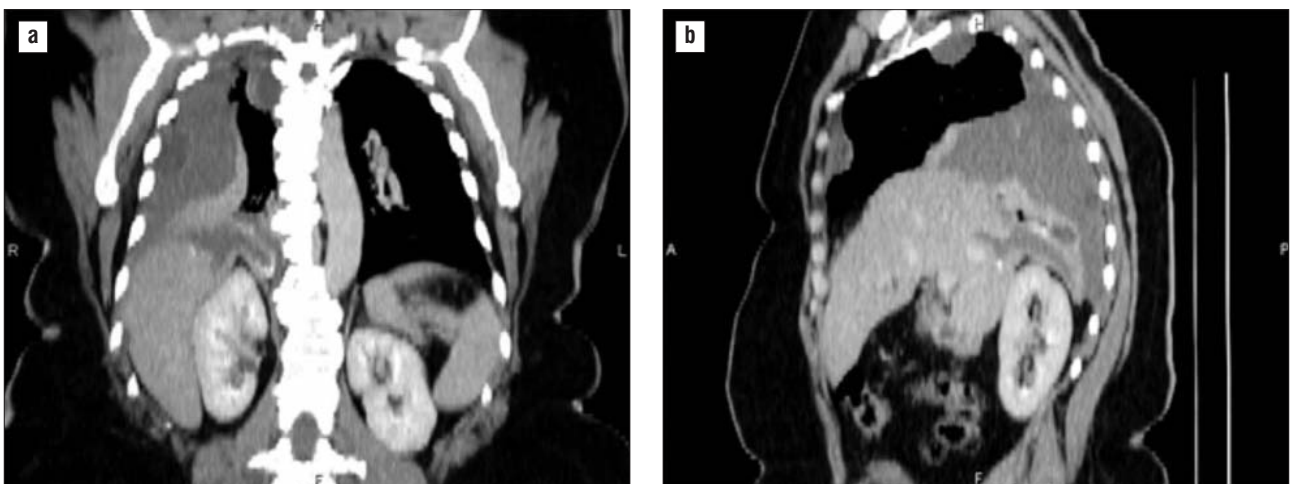
In one case (case 3) a thoracic approach with phrenotomy was preferred, with drainage of the thoracic collection and partial cystectomy for the liver cyst. No abdominal incision was used for this patient.

In the fourth (case 4) case an abdominal approach with phrenotomy was chosen, with complete cystectomy of the liver cyst and thoracic collection drainage. No thoracotomy was used for this patient.

**RESULTS**

The postoperative course was uneventful in 1 cases (Case 1), with discharging of the patient in day 5 after surgery. Wound infections were observed in two patients (case 2 and case 4). Treatment consisted in local antiseptis. One patient (case 3) had a persistent biliary fistula that dried up with drainage and lavage.

One deaths in our series was seen during our short experience and occurred in patient no. 4, who



**Figure 1 - CT-scan showing thoracic and liver contiguous lesions**

developed in the 4<sup>th</sup> postoperative day acute pulmonary embolism.

## DISCUSSIONS

Thoracic complications of hepatic hydatid cyst are seen in approximately 2% to 11% of cases (1,2).

The main postoperative complication and life-threatening factor is severe infection. Several factors participate in promoting intrathoracic evolution of hydatid cysts of the hepatic dome (3) the intrathoracic negative pressure tends to aspirate the hepatic hydatid cyst, the mechanical compression maintained by the cyst on the diaphragm results in local ischemia, which can lead to muscle erosion, sepsis in the hepatic cyst can also contribute to muscle necrosis close to the cyst and in the case of biliary fistulas, the caustic property of biliary secretions can lead to chemical erosion of the diaphragm and the bronchi.

Once the diaphragmatic gap exists, the cyst often faces strong pleural adhesions. In this case rupture occurs directly into the bronchial tree through a fistular path (type I) 2 or after creating an intraparenchymal suppurative cavity containing hydatid material and sometimes biliary secretions (type II) 2. In the case of pleural adhesions, the progression can also be to an encysted pleural pouch that communicates with the hepatic cyst (type III) 2. The pleural pouch can rupture into the bronchi or find a way through the thoracic wall, creating a pleuroparietal fistula.

Less commonly the rupture appears acutely in the pleural cavity (type IV) 2, resulting in a hydatid and biliary empyema. This rapid evolution through the diaphragm is the consequence of both sepsis and biliary secretions on muscle. The rupture can also occur silently and result in secondary pleural hydatidosis due to spreading of the pleura with living scolices.

With regard to the liver, the presence of biliary fistulas and biliary duct status are of great importance to the prognosis and evolution of this disease. However, no parallel can be drawn between biliary lesions and thoracic lesions. Major intrathoracic damage can be seen without biliary fistulas or biliary duct obstruction. The worst situation is the type associated with a large-caliber fistula connecting the biliary duct to the bronchial tree through the liver cystic cavity. In this case severe infection is associated with profuse bile leakage that results in metabolic disorders due to electrolyte and fluid loss. Furthermore, the caustic effect of biliary secretions on the bronchial tree induces respiratory distress syndrome (4-7).

We believe CT-scan to be the best examination for

assessing biliary, hepatic, diaphragmatic, and pleuro-pulmonary lesions. The therapeutic approach thus depends on CT-scan findings, thoracotomy, laparotomy, or a combined thoracic and abdominal approach. Surgical treatment has five goals (7-9): to treat the liver cyst; to make sure there is free-flowing biliary fluid; to perform hepatodiaphragmatic disconnection; to treat intrathoracic lesions; and to restore the diaphragm. The three first goals can be realized using an isolated abdominal approach, which is satisfactory if there is no intrathoracic damage, especially for type I disease in Mestiri classification (2). Sometimes type IB cysts can produce bronchial lesions that can lead to localized bronchiectasis, requiring further parenchymal resection. The thoracic approach is necessary for type II, III, and IV intrathoracic ruptures because the intrathoracic suppurated collection cannot be treated via laparotomy. If clinical, laboratory, and imaging findings indicate biliary duct involvement, laparotomy becomes necessary, even though selected patients can undergo endoscopic sphincterotomy to avoid combined thoracic and abdominal approaches.

Intrathoracic hepatic hydatid cyst rupture is a serious situation because of the complexity of the lesions; they are often difficult to treat by a one-stage operation, and the patients are often in a poor general state. Therefore mortality is high, ranging from 9% to 43% in the literature (2,3,9-11). Recurrence may be observed during follow-up (11,12, 13,14).

## CONCLUSIONS

Thoracic complications of hydatid cyst of the liver in most cases are easy to diagnose with noninvasive, low-cost techniques as the echography, but CT-scan bring new information needed to correctly assess the extension of the disease. We believe CT-scan to be the best method for confirming the diagnosis (6,15), evaluating free flow of the biliary tract, and detecting intrathoracic suppurated collections, and also offers information about pleural and parenchymal damage that cannot be seen accurately with ultrasonography (16-20).

## REFERENCES

1. Beltran de Heredia JM. Transitos hidatidicos hepatotoracicos. In Proceedings of the XIII Congreso Internacional de Hidatidologia. Madrid, Sociitt Internationale d'Hydatidologie. 1985; p. 281-288.
2. Mestiri S, Kilani T, Thameur H, Sassi S. Les migrations thoraciques des kystes hydatiques du foie: proposition d'une classification. Lyon Chir. 1987;83:12.
3. Kilani T, Daoues A, Horchani H, Sellami M. Place of thoracotomy in thoracic complications of hydatid cysts of the liver. Ann Chir. 1991;45(8): 705-10. French

4. Zaouche A. La chirurgie des kystes hydatiques du foie. In: Proceedings of the XV Congress of the Tunisian Association of Surgery, Tunis, Association Tunisienne de Chirurgie. 1994.
5. Brunetti E, Kern P, Vuitton DA. Expert consensus for the diagnosis and treatment of cystic and alveolar echinococcosis in humans. *Acta Trop*. 2010 Apr;114(1):1-16.
6. Marrone G, Crino F, Caruso S, Mamone G, Carollo V, Milazzo M, et al. Multidisciplinary imaging of liver hydatidosis. *World J Gastroenterol*. 2012 Apr 7;18(13):1438-47.
7. Gómez R1, Moreno E, Loinaz C, De la Calle A, Castellon C, Manzanera M, Herrera V, Garcia A, Hidalgo M. Diaphragmatic or transdiaphragmatic thoracic involvement in hepatic hydatid disease: surgical trends and classification. *World J Surg*. 1995 Sep-Oct;19(5):714-9; discussion 719.
8. Gharbi HA, Hassine W, Brauner MW, Dupuch K. Ultrasound examination of the hydatid liver. *Radiology*. 1981 May;139(2):459-63.
9. Sellami M. L'échographie de l'hydatidose thoracique. *Med Chir Dig*. 1989; 18:305.
10. Yuste MG, Duque JL, Heras F, Sanchez E, Gonzalez Selma ML, Ramos G, et al. Thoracic development of liver hydatid cysts, and its complications. Apropos of 21 cases. *Ann Chir*. 1984 Mar;38(2):153-7. French
11. Freixinet JL, Mestres CA, Cugat E, Mateu M, Gimferrer JM, Catalán M, et al. Hepaticothoracic transdiaphragmatic echinococcosis. *Ann Thorac Surg*. 1988 Apr;45(4):426-9.
12. Sakhrí J, Ben Ali A, Letaief R, Derbel F, Dahmen Y, Ben Hadj Hmida R. Hydatid cysts of the liver ruptured into the thorax. Diagnostic and therapeutic aspects *J Chir (Paris)*. 1996;133(9-10):437-41. French
13. Ergüney S, Tortum O, Taspınar AH, Ertem M, Gazioglu E. Complicated hydatid cysts of the liver. *Ann Chir*. 1991;45(7):584-9. French
14. Moro P, Schantz PM. Echinococcosis: a review. *Int J Infect Dis*. 2009 Mar;13(2):125-33.
15. Silva MA, Mirza DF, Bramhall SR, Mayer AD, McMaster P, Buckels JA. Treatment of hydatid disease of the liver. Evaluation of a UK experience. *Dig Surg*. 2004;21(3):227-33.
16. Khuroo MS, Wani NA, Javid G, Khan BA, Yattoo GN, Shah AH, et al. Percutaneous drainage compared with surgery for hepatic hydatid cysts. *N Engl J Med*. 1997 Sep 25;337(13):881-7.
17. Kabaalioglu A, Ceken K, Alimoglu E, Apaydin A. Percutaneous imaging-guided treatment of hydatid liver cysts: do long-term results make it a first choice? *Eur J Radiol*. 2006 Jul;59(1):65-73.
18. Giorgio A, Di Sarno A, de Stefano G, Liorre G, Farella N, Scognamiglio U, et al. Sonography and clinical outcome of viable hydatid liver cysts treated with double percutaneous aspiration and ethanol injection as first-line therapy: efficacy and long-term follow-up. *AJR Am J Roentgenol*. 2009 Sep;193(3):W186-92.
19. Peláez V, Kugler C, Correa D, Del Carpio M, Guangioli M, Molina J, et al. PAIR as percutaneous treatment of hydatid liver cysts. *Acta Trop*. 2000 Mar 25;75(2):197-202.
20. Caremani M, Lapini L, Caremani D, Occhini U. Sonographic diagnosis of hydatidosis: the sign of the cyst wall. *Eur J Ultrasound*. 2003 Feb;16(3): 217-23.